A Neural Network System for Menisci Surface Estimation in MR Discrete 3D Scenes

M. Rucci*, M. Spuri*, C. Perego°
*ARTS Lab, Scuola Superiore S.Anna, Pisa, Italy
°Esaote Biomedica, Genoa, Italy

Abstract-**Menisci pathologies are more easily assessed if images represented on planes parallel to the menisci major section are examined. In the case of magnetic resonance imaging (MR), this procedure requires the physician to locate the plane where the two menisci approximately lie. Unfortunately, this operation is time-consuming and it is often accomplished by successive refinements.**

In this paper we propose a system for the automated location of such plane. The system works on sets of MR sagittal tomograms and includes three modules, two of which, those performing the image understanding tasks, are based on neural networks. Satisfactory results have been obtained with short computation time.

I. INTRODUCTION

The diagnosis of meniscus pathologies is a critical problem in orthopaedics. Clear images of menisci are extremely heplful for such diagnosis. Currently used medical imaging techniques are Magnetic Resonance (MR) and Computerized Tomography (CT), which produce sequence of tomograms representing planar sections of the examined structure. Usually, the physician examines several tomograms obtained with successive acquisitions and, among them, he chooses the most meaningful for the diagnosis. A commonly used criteria is to analyse a sagittal tomogram in order to evaluate the slope of a perpendicular intersecting plane that most likely intercepts the meniscus section. The images contained in a set of parallel planes, all with the determined slope, are obtained with new acquisitions (if possible) or with the operation of reslicing from other tomograms [1], and then used for the diagnosis. However, this procedure does not assure that both menisci lie along the calculated slope. In fact, since the plane parameters are estimated on only one sagittal tomogram, the plane itself is restricted to be perpendicular to the sagittal section.

In this paper we propose a system based on neural networks for the automated location of a meniscus intersecting plane. The system works on a discrete 3D scene [1] composed of a set of MR sagittal tomograms, and evaluates the slope of the menisci section on each image. In this way a ruled surface is produced and its best interpolating plane is then estimated with the Least Mean Squares (LMS) algorithm. As a secondary output, the system is also able to calculate the image contained in the estimated ruled surface and to project it on an axial plane.

This method is more accurate than the currently used manual procedure. We believe that the images obtained with the plane slope thus determined are more meaningful from a diagnostic point of view than those obtained manually, since this slope is the result of a real 3D examination of the scene. In addition, the automation of the menisci plane location eliminates the boring procedure of successive refinements and speeds up the overall investigation.

Neural networks [2][3] and image analysis at different level of resolution [4] have allowed the achievement of a trade-off between system speed and overall performance. In addition, both have contributed to decrease the sensitivity to biological variability, structures displacement and image noise.

II. SYSTEM DESCRIPTION

As shown in Fig.1 the system comprises three modules: a Region Of Interest Focusing Module (ROIFM) a Surface Estimating module (SEM) and an Interpolating Module (IM). The first two modules include neural networks, which were trained with the back-propagation algorithm.

The system examines sequentially the tomograms of the scene. At first the ROIFM finds the joint of the knee on the the input image. In this way a window is positioned on the tomogram giving a limited Region Of Interest (ROI). The dimensions of the ROI are settled *a priori* so as to include largely the joint area. The ROI is then sent to the SEM which approximates linearly the axis of the intersection

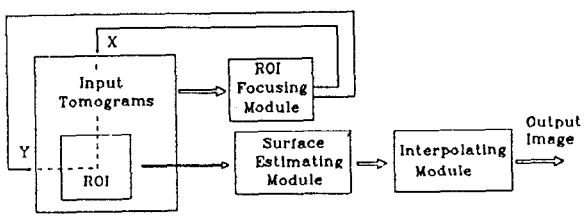

Fig. 1 System architecture

0-7803-0785-2/92$03.00 ©IEEE

between menisci and image plane. By repeating this operation on each tomogram of the scene a ruled surface is found.

The IM operates on the outputs of the SEM when all the tomograms of the scene have been processed by the first two modules. The IM looks for the plane that best interpolates the ruled surface with a modified version of the LMS algorithm.

Both the ROIFM and the SEM consist of two sub-modules: a Gaussian Decimator (GD) and an appropriately trained neural network. The GD reduces the resolution of the input image by resampling it with a wider step. At the same time the GD filters the image with a gaussian mask in order to save low-frequency information. In both the modules the outputs of the GD are 16 pixels wide images, which are processed by the following nets. Part of the information present in the tomogram is lost; nevertheless, the preserved information is still sufficient for the considered tasks, and the jobs of the neural networks are made easier by having eliminated irrelevant details. Furthermore, a certain invariance to structure displacements and to biological variability is achieved, in addition to good noise rejection.

The structure of the neural networks is depicted in Fig.2. They are full-connected feed-forward nets consisting of four layers, with a sigmoid activation function. After the second layer each net is split in two sub-networks so that the outputs are subdivided in two sets, each one coding a different value. In the ROIFM the outputs of the net give the coordinates of the central pixel of the ROI, while the net included in the SEM determines the position of a line on the tomogram by means of the y coordinates of the two pixels where the line intersects the ROI edge. The adopted structure and the code were choosen experimentally by optimizing network performance. The input layers consist of 256 units in both modules, while the remaining layers have N=32 units in the ROIFM, and N=20 in the SEM.

III. RESULTS

All the networks were trained on a set of 88 images

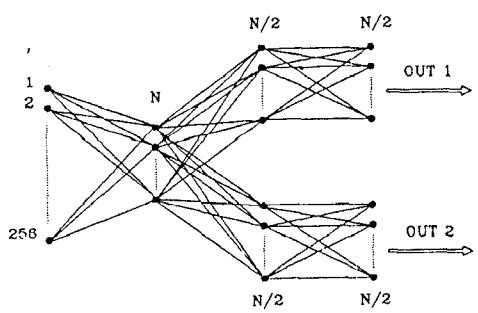

Fig.2 Structure of the nets in the ROIFM and in the SEM.

TABLE I

PERFORANCE OF THE ROIFM

Patient	Mean	Variance
A	0.48	0.16
B	1.03	0.33
C	0.80	0.18
D	0.86	0.37
E	0.82	0.16
TEST	4.40	4.96

TABLE II

PERFORMANCE OF THE SEM

Patient	Mean Y_1	$\sigma^2(Y_1)$	Mean Y_2	$\sigma^2(Y_2)$
A	0.33	0.02	0.36	0.05
B	0.29	0.02	0.43	0.18
C	0.49	0.46	0.61	1.42
D	0.23	0.03	0.27	0.08
E	0.39	0.12	0.28	0.05
TEST	3.47	4.09	2.13	3.21

(whose dimensions were 256x256 pixels) pertaining to 5 patients. The performance of the ROIFM and of the SEM on the patients included in the training set as well as on a test patient, are displayed in table I and II, respectively. The data, expressed in pixels on the original tomogram, show the low error of the system when compared with the output formulated by the physician. The proposed method requires short computation time: the estimate of the plane slope in a single sagittal tomogram takes 0.2s on a CPU 80486 with a 33 MHz clock frequency. This period should be multiplied for the number of tomograms and added to that of the IM in order to obtain the overall elapsed time.

REFERENCES

[1] J.K. Udupa, "Display 3D information in discrete 3D scenes produced by computerized tomography", *IEEE Proccedings* 71 (1983), pp. 420-431.

[2] D.E. Rumelhart, J.L. McClelland, *Parallel Distributed Processing*, Cambridge, MIT Press 1986.

[3] P.K. Simpson, *Artificial Neural System*, New York, Pergamon Press 1990.

[4] P.J.Burt, "Smart Sensing within a Pyramid Vision Machine", *IEEE Proceedings*, 76 (1988), pp. 1006-1015.